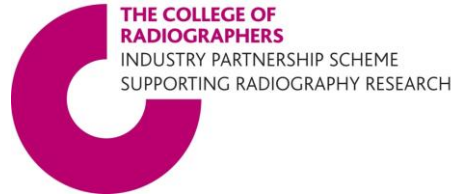


For office use only

Grant ID:



College of Radiographers Industrial Partnership Research Grants Final Report Form

Please use the tab key to move to next question

| | |
|---|---|
| 1. Principal Investigator | Dr John Cathcart |
| 2. Project Title | <i>High resolution Magnetic Resonance (MR) imaging for the assessment of the buttocks in spinal cord injury,</i> |
| 3. Amount of Grant | £10,056 |
| 4. Did you spend the money as indicated in your proposal (if not why)? | Yes and as agreed if any amendments required |
| 5. Did you reach your intended project outcomes (if not why)? | Yes |
| 6. What are your significant findings? | That the anatomy under the Ischial Tuberosities is variable between subjects and that fatty infiltration is inconsistent between subjects. Thus the causation factors for pressure ulcer development need further investigation in regards shearing and anatomical factors. |
| 7. Have you submitted the work for publication (if so where)? | Yes. |
| 8. Have you presented the work at a national/international event (if so where)? | Yes. RSNA 2016, CoRIPS conference Jan 2015 |
| 9. Please provide an executive summary of your work (two sides of A4 maximum) N.B. If you already have a draft or final version of the proposed publication can you please attach. | Sonenblum, SE., Sprigle, SH., Cathcart, JM. and Winder, RJ. 3D Anatomy and Deformation of the Seated Buttocks. Journal of Tissue Viability. Apr 2015. |

9. Return of final report form

Please return this form to:

Professional and Education Administration Team
The Society & College of Radiographers
207 Providence Square
Mill Street
London
SE1 2EW

Or by email at pande@sor.org

Executive Summary

The pilot work took slightly longer than anticipated but the objectives were met.

In the end 4 ambulant subjects were scanned, 2 female and 2 male. This was followed by 3 spinal cord injury subjects.

Each of the scans were performed in Atlanta on the fonar upright scanner. Subjects were scanned unloaded and on 3 makes of cushions.

The image analysis of each subject was carried out by myself to identify the various types of anatomy and then segmented in 3 planes. From this measurements were undertaken and 3D images were then generated with segmenting and colour coded.

The 2 attached papers demonstrate the outcomes and understanding developed.

This pilot work has led to the research team being able to bid and achieve a NIH grant and now 65 subjects have been scanned and the work is ongoing and continuing to develop and expand.

It is thanks to initial funding from CoRIPS that this has been possible.